

**INTERNATIONAL JOURNAL OF ADVANCES IN
PHARMACY, BIOLOGY AND CHEMISTRY**

Research Article

**Evaluation the protective effect of *Aloe vera* against
radiation induced hepatic toxicity in Swiss albino mice**

Priyanka Dadupanthi

Department of Zoology,

University of Rajasthan, Jaipur, India - 302004.

ABSTRACT

The radiomodulatory effect of *Aloe vera* was studied in liver of Swiss albino mice. Animals were divided into two groups. Animals of group I administered *Aloe vera* (drug) and control set of group II were given radiation only where as animals experimental set of group II were administered by *Aloe vera* + Radiation. Histopathology was assessed at different intervals of post-irradiation from day ¼, and 1 post irradiation. Results suggest that *Aloe vera* modulate the radiation induced pathological alterations in Swiss albino mice.

Keywords: Radioprotection, *Aloe vera*, Swiss albino mice, Histopathology.

INTRODUCTION

Various radioisotopes, gamma radiation and x-rays are being used considerably in medical sciences both for diagnostic and therapeutic purposes. Release of radioactive nuclides into atmosphere or ground water or both has increased due to underground testing of nuclear weapons. In industrial and technological areas growing applications of radiation have amazingly increased the risk for workers either by low dose exposure over a long term period or unpredictable accidental exposure. Nowadays exposure of cosmic radiation and background radiation are also increasing continuously. Radiation produces free radicals which are hazards for human beings. The potential application of radioprotective chemicals in the event of planned exposures or radiation accidents/incidents has been investigated. But successes of these chemical compounds are limited because of their high toxicity. Due to this various plant extracts and herbal preparations have been studied to have radio protective action *in vivo* and *in vitro* studies^{1,2,3,4}. Since several thousands of year's *Aloe vera* used medicinally, it belongs to Aloaceae family. It has rejuvenating, healing or smoothing properties. *Aloe vera* has two parts- latex

and gel. Latex contain anthraquinone glycosides (Aloin, Aloe emodin) that are potent laxatives, laxative effect from *Aloe* is stronger than any other herb. Herbal medicine is still the mainstay of about 75-80% of the world population, mainly in the developing countries, for primary health care because of better cultural acceptability, better compatibility with the human body and lesser side effects. One such popularly known and used plant is *Aloe vera* *barbadensis* belonging to family Liliaceae and consists of about more than 250 species. It is commonly called "Guar -patha" or Ghee-Kuar. It is rich in vitamin A, E, C and Zinc and Selenium. It is reported to have antioxidant, anti-tumor and anti-inflammatory activities.

Liver is an important metabolic organ because it plays a key role in removing excess calcium, magnesium and iron internally and also important in food digestion.

Therefore, this study was undertaken to evaluate the value of nutritional supplementation of *Aloe vera* against the radiation induced damage on the liver of Swiss albino mice.

MATERIALS AND METHOD

Animals

Male Swiss albino mice 6-8 weeks old 24±2g were used, they were given standard mice feed and water. The maintenance and handling of the animals were done according to the guidelines of the Committee for the Purpose of Control and Supervision of Experimental Animals, Ministry of Environment and Forests, Government of India. All the experimental work was approved by the institutional animal ethics committee.

Source of radiation

Animal were treated with cobalt-60 source of radiation in radiotherapy Dept. SMS hospital, Jaipur. On exposure to radiation, animals were kept in a ventilated box and the radiation dose given to these animals were 0.5 Gy.

Aloe vera cold extract

The *Aloe vera* leaf is collected locally. The specimen was placed at Herbarium, Dept. of Botany, University of Rajasthan, and Jaipur. The voucher number is RUBL-19886. *Aloe vera* extract is prepared by peeling, drying in powder form and these residue of *Aloe vera* extracted with ethyl alcohol double the volume of leaf extract and keeping at a room temperature for evaporation & this process is repeated for three times and finally kept in incubator at 37°C for complete evaporation at 24 hours, then the concentrated extract are ready for oral administration.

Experimental Design

For this study, selected adult male Swiss albino mice were divided into two groups. Group II is divided into two sets.

Group I: Animals of this group were administered *Aloe* extract orally at the dose of 1000 mg /kg body weight (once in a day) for 15 consecutive days to study its toxic effects on liver, if any.

Group II: Group II was divided into two sets, one was experimental and another was control. Animals of experimental set were administered *Aloe* extract orally at the dose of 1000 mg /kg body weight (once in a day) for 15 consecutive days, whereas animals of control set were given double distilled water (DDW) orally (volume equal to that used for *Aloe* administration in experimental sets) for 15 consecutive days. Just after 1 hour of last administration of extract and DDW, animals of group

II were exposed to sublethal dose 0.5 Gy gamma radiation.

Parameters Studied:

A minimum of 5 animals from group I and each set of control and experiment were sacrificed by cervical dislocation at day ¼, and 1 post irradiation and liver was taken for histopathological studies.

Histopathology:

For histopathological study, a small piece of liver was taken from each animal before it was perfused with chilled saline, fixed in Bouin's fluid for 24 hours and after processing, paraffin sections were cut and stained with Harris haematoxylin and eosin.

RESULT

Animals of group I showed normal hepatic architecture. No change was seen in cytoplasm and nuclei of the hepatocytes (Fig. 1).

Liver of control set (irradiated alone) exhibited mild dilation of sinusoids, enucleated hepatocytes and lymphocytic infiltration at 6 hours post irradiation. No cytoplasmic changes were seen in hepatocytes but mild shrinkage and crenation of nuclei were observed at this autopsy interval (Fig.2). On the other hand, liver of *Aloe* treated 0.5 Gy irradiated mice showed normal cord like arrangement of hepatocytes but kupffer cell population and binucleated hepatocytes increased along with lymphocytic infiltration (Fig. 3). Maximum hepatolesions were noticed at day 1 in 0.5 Gy irradiated alone animals. Degranulation and vacuolization of cytoplasm, enucleated hepatocytes, lymphocytic infiltration, increased kupffer cell population and fatty degeneration also increased at day 1 post irradiation. Severe shrinkage and crenation of nuclei were the other observed radio lesions in liver at this autopsy interval (Fig.4). However, mice liver of experimental set (*Aloe* treated 0.5 Gy irradiated) exhibited fatty degeneration, enucleated hepatocytes, degranulation and vacuolization of cytoplasm, shrinkage and crenation of nuclei, at day 1 post irradiation (Fig.5).

DISCUSSION

Effects of radiation on liver were not clear in the beginning and therefore it remained a controversial organ for a long time for its radiosensitivity. Even the eminent workers failed to observe any visible pathological change in hepatic tissue following exposure to moderate or large doses of radiations⁵.

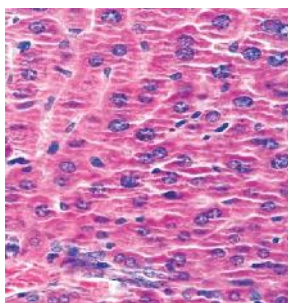


Fig. 1: Drug Alone

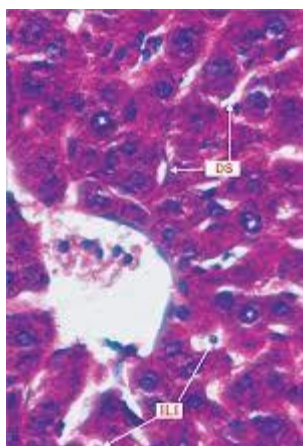


Fig. 2: 6 hours Control (0.5 Gy)

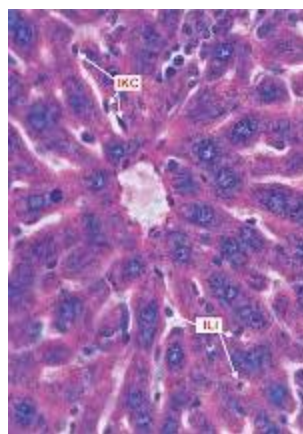


Fig. 2: 6 hours Experimental (*Aloe*+0.5 Gy)

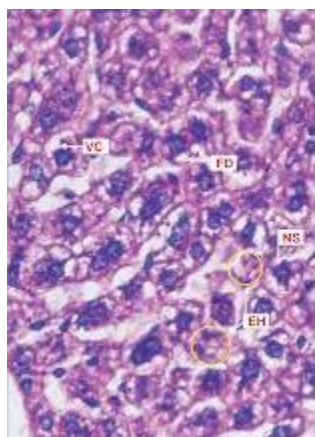


Fig. 4: Day 1 Control (0.5 Gy)

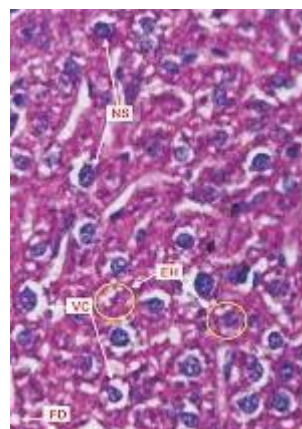


Fig. 5: Day 1 Experimental (*Aloe*+0.5 Gy)

Reports of several workers indicate that severe parenchymal changes were produced in liver following exposure to different doses of radiation^{6,7}. Similarly, workers also showed radiosensitive nature of the liver even to low and moderate doses of radiation⁸⁻¹³.

In the present study, types of histopathological changes and recovery pattern were observed in mice exposed to 0.5 Gy gamma radiations (control set). Even after irradiation with the lowest dose (0.5 Gy) mild histopathological changes such as dilation of sinusoides, lymphatic infiltration, enucleated hepatocytes and shrunken and crenated nuclei were noticed in liver cells at 6 hours post irradiation, but cytoplasmic changes were absent (Fig.2). Maximum hepatolesions were noticed at day 1 (Fig.4). In response to radiation formation of binucleated and /or mononucleated giant cells in liver is earlier reported by several workers^{14-16,8}.

Liver of *Aloe* treated 0.5 Gy irradiated mice showed normal cord like arrangement of hepatocytes at 6 hours post irradiation but at day 1, increased population of kupffer cells, binucleated hepatocytes and lymphocytic infiltration were evidently seen (Figs.2, 4). Resarchers also observed that pretreatment of *Emblica* protect the radiated liver cells against pyknotic and crenated nuclei, moderate dilation with most of the compacted hepatocytes, large area of cellular infiltration and hyperaemia of liver sinusoid¹⁷. *Aloe* has a protective effect on histological damage by maintaining membrane integrity due to its direct action of free radicals¹⁸.

It was concluded by researchers that oral administration of aqueous leaf extract of *E. alba* had detrimental effects on histopathological alterations in liver of female Swiss albino mice¹⁹.

Some reports also showed that herbicide, 3 amino-1, 2-triazole provides slight protection to mouse liver against radiation induced damage^{17,18}. Similarly, treatment with cystamine¹⁹, cysteamine²⁰ and serotonin^{21,22} provided protection to liver against radiation induced damage, which is in agreement with present findings.

CONCLUSION

Thus, results of this study indicate that radioprotective effect of *Aloe* manifested in various forms in liver. Treatment with *Aloe* prior to irradiation reduced the magnitude (severity) of radiation induced various histopathological changes (distortion in hepatic architecture, crenation, shrinkage and loss of liver cells nuclei, degranulation and vacuolization of cytoplasm, lymphatic infiltration and dilation of sinusoids) and therefore, increase in kupffer cell population was inhibited in mice liver.

Treatment also enhanced the recovery process and prevented the formation of radiation induced giant hepatocytes.

ACKNOWLEDGEMENTS

Author is gratefully acknowledging Head, Department of Zoology, University of Rajasthan (India) for providing necessary facilities in the department. The irradiation facility provided by the Radiotherapy Department of S. M. S. Hospital, Jaipur (India) is also thankfully acknowledged.

REFERENCES

1. Shinoda M. Studies on chemical radioprotectors against X-irradiation used by soft X-ray accelerator. *Yakugaku Zasshi* 1995, 115(1): 24-41.
2. Kumar P, Kuttan VR, Kuttan G. Radioprotective effects of *Rasayans*. *Ind. J. Exptl. Biol.* 1996, 34: 848
3. Uma Devi P, Ganasoundari A. Modulation of glutathione and antioxidant enzymes by *ocimum sanctum* and its role in protection against radiation injury. *Ind. J. Exptl. Biol.* 1999, 37(3):262-264.
4. Kamat JP, Baloar KK, Devasagayam TP, Venkatachalam SR. Antioxidant properties of *asparagus recemosus* against damage induced by gamma radiation in rat liver mitochondria. *J. Ethnopharmacol*, 2000;71(3): 425-435.
5. Hall CC, Whipple GH. Roentgen intoxication: Disturbance in metabolism produced by deep massive doses of hard roentgen rays. *Am. J. Sci.* 1919; 15:453.
6. Kolodny A. Tissue changes after experimental deep roentgen irradiation, *Am. J. Path.* 1925, 1(3):285-294.
7. Ballinger I, Inglis D. Free radical induced lipid peroxidation damage and its inhibition by vitamin E and selenium. *Fed. Proc.* 1933, 24: 73.
8. Gupta ML, A comparative study on the radioresponse of liver in vertebrates. Ph.D. thesis, University of Rajasthan, Jaipur, India, 1980.
9. Gupta ML, Uma Devi P. Formation of giant hepatocytes in response to radiation. *Curr. Sci.* 1981, 50(14): 637-638.
10. Taj R, Study of combined effect of ionizing radiation and lead acetate (metallic Pollutant) on liver and spleen of Swiss albino mice with and without radioprotective drug. Ph. D. thesis, University of Rajasthan, Jaipur, India, 1991.
11. Purohit RK, Modification of radiation induced changes in mammalian skin and liver by Liv.52.

- Ph.D thesis, University of Rajasthan, Jaipur, India, 1996.
12. Saxena A, Enterohepatic response against the combined effect of mercury and radiation in mice and its modification by Liv. 52. Ph D. thesis, University of Rajasthan, Jaipur, India, 1997.
 13. Maharwal J, Samarth RM, Saini MR, Antioxidant effect of *Rajgira* leaf extract in liver of Swiss albino mice after exposure to different doses of gamma radiation. *Phytother. Res.* 2005, 19(8):717-720.
 14. Koletsky S, Gustafson G. Liver damage in rats from radioactive colloidal gold. *Lab. Invest.* 1952, 1(3): 312-323
 15. Montgomery PO, Reynalods D, Clendon D. Cellular and sub cellular effects of ionizing radiations. *Am. J. Path.* 1964, 44: 727.
 16. Saini MR. The protective effect of 2-MPG (Thiola) against radiation induced changes in hematopoietic tissues of Swiss albino mice after external irradiation. Ph.D. Thesis, University of Rajasthan, Jaipur, India, 1977.
 17. Bhati SL, Agarwal M, Chakrawarti A, Purohit RK. Chemopreventive action of *emblica officinalis* against radiation and cadmium induced hepatic lesions in swiss albino mice, *IJPSR*, 2016; 7(1): 370-376.
 18. Purohit RK, Bhati SL, Purkharam, Isran R, Agarwal M Chakrawarti A. Radiation and cadmium induced testicular injury and its amelioration by *Aloe Vera* extract, *Int J Pharm Bio Sci.* 2015 April; 6(2): (B) 821 – 829.
 19. Singh T, Sinha N, Singh A. Biochemical and histopathological effects on liver due to acute oral toxicity of aqueous leaf extract of *Ecliptaalba* on female Swiss albino mice *Indian J Pharmacol.* 2013 Jan-Feb; 45(1):61-5.
 20. Friedburg W. Effect of reduced liver and kidney catalase concentrations on lethality of X-irradiation on rats. *Proc. Soc. Exptl. Biol. Med.* 1956, 93(1): 52-53.
 21. Doul MM, VandeKerkhof PC, VanVlijmen IM, DeBakker ES, Zwiars F, DeJong EM. The efficacy of a new topical treatment for psoriasis: *Eur. J. Acad. Dermatol.* 1961,11(1):13-18.
 22. Chatterjee PD, Bose A. Determination of dry mass of rat liver cells to study the protective mechanism of cysteamine against whole body X-irradiation. *Exptl. Cell. Res.* 1962, 27:168.
 23. Eldjarn L, Quoted by neuron, K.F.C. "Current topics in radiation research", Elbert, M. and Howard, A. (Eds.), North Holland Publishing Co. Amsterdam. 1964, Vol. IV, 54.
 24. Vittorio PV, Wright EW, Sinott BE. A study of the protective effect of serotonin against whole body X-irradiation in mice with the aid of Cr⁵¹. *Cand. J. Biochem. Physiol.* 1963, 41(2):347-360.
 25. Atherton P. *Aloe vera: magic or medicine?* *Nurs. stand.* 1998, 12: 49.