

**INTERNATIONAL JOURNAL OF ADVANCES IN
PHARMACY, BIOLOGY AND CHEMISTRY****Research Article****The Effects of *Aframomum melegueta* Aqueous
Extract on the Liver of Adult Wistar Rats****Obike H I¹, Ezejindu D N¹, Akingboye A. J¹, Ezejindu C. N².**¹Department of Anatomy, College of Health Sciences, Nnamdi Azikiwe University,
Nnewi Campus, Anambra State, Nigeria.²Department of Microbiology, Abia State University, Uturu, Abia State, Nigeria.**ABSTRACT**

Aframomum melegueta of the family *Zingiberaceae* is a spice used in West Africa for the purpose of alleviating stomachache, diarrhea and hypertension. The aim of this study is to evaluate the effects of *Aframomum melegueta* on the liver of adult wistar rats. Twenty wistar rats weighing between 180-215kg were used. They were grouped into four groups of five animals. Group A served as the control and received 0.35ml of distilled water, the experimental groups B,C & D received 0.55ml, 0.65ml and 0.75ml of aqueous extract of *Aframomum melegueta* respectively for twenty eight days. Twenty four hours after the last administration, the animals were weighed, anaesthetized using chloroform inhalation method and dissected. Liver tissues were removed, weighed and trimmed down to a size of 3mm × 3mm thick and fixed in 10% formalin for histological studies. There were body weight gain in the experimental groups compared with the control. The organ (liver) weight of the experimental groups were statistically similar with the control. There was no apparent toxicity assessed by histological examination.

Keywords: *Aframomum melegueta*, Liver weight, Body weight, Hepatoprotective, Wistar rats.

INTRODUCTION

Aframomum melegueta of the family *zingiberaceae* is a spice in the ginger family with the common name "Alligator pepper"¹. The spice is used in West Africa for the purpose of alleviating stomachache and diarrhea¹ as well as hypertension² with some limited reports on it being used for tuberculosis³ and a remedy for snakebites and scorpion stings⁴. The seeds are used for culinary reasons (due to the pungency of the seeds, it is common used as seasoning on food products⁵.

The seeds also tend to have general anti-microbial properties similar to many spices^{5, 6} and has some molluscidal⁷ and repellent^{8,9} properties as well. It is one of many pungent herbs said to aid in sexuality and aphrodisiac¹⁰.

Aframomum melegueta appears to have a polyphenolic content of $2.28 \pm 0.02\text{mg/g}$ (0.2% dry

weight) with 0.55mg/g (0.06%) flavinoids which is comparatively high to other Africa spices tested although low relative to other herbs¹¹.

This study is aimed at investigating the effects of *Aframomum melegueta* on the liver of adult wistar rats.

MATERIALS AND METHODS**Breeding of Animals**

Twenty healthy adult wistar rats were procured from the animal house of Anatomy Department University of Calabar, Cross River State and bred in the animal house of Nnamdi Azikiwe University, Nnewi Campus. They were allowed for seven days acclimatization under normal temperature before their weights were taken. They were fed ad libitum with water and guinea feed pellets from Agro feed mill Nigeria Ltd.

Drug Preparation

Aframomum melegueta were obtained from Nkwo market in Nnewi Anambra State, Nigeria and grinded into powder with a grinding machine. 200mg/1kg body weight were dissolved in 5mls of distilled water and administered to the animals.

Experimental Protocol

The twenty healthy adult wistar rats were allocated into four groups (A, B, C & D) of five animals each. Group A served as the control and received 0.35ml of distilled water, the experimental groups (B, C & D) received 0.55ml, 0.65ml and 0.75ml of aqueous extract of *Aframomum melegueta* respectively for twenty eight days. The control and experimental groups were anaesthetized using chloroform inhalation method and dissected, liver tissues were removed, weighed, trimmed down and fixed in 10% formaldehyde for histological studies.

Tissue Processing

The tissues were transferred into an automatic processor where they went through a process of fixation, dehydration, clearing, infiltration, embedding, sectioning and staining. Fixation was carried out in 10% formaldehyde. The tissues were washed over night in running tap water after four hours in 10% formaldehyde. Dehydration of the fixed tissues were carried out in different percentages of alcohol 50%, 70% and 90% absolute. The tissues were then cleared in xylene and embedded in paraffin wax. Serial sections of 5micron thick are obtained using a rotatory microtome. The tissue sections were deparaffined hydrated and stained using the routine haematoxylin and eosin method. The stained sections were then examined under the light microscope.

RESULTS

Morphometric Analysis of Body Weights

Table 1: Comparison of mean initial and final body weight and weight change in all the groups (A, B, C & D)

	GROUP A	GROUP B	GROUP C	GROUP D	F-RRATIO	PROB OF SIG
INITIAL BODY WEIGHT	190.20 ± 2.30	192.20 ± 3.60	193.40 ± 4.10	194.10 ± 2.70	64.240	<0.001
FINAL BODY WEIGHT	215.30 ± 4.20	219.40 ± 3.50	220.70 ± 3.20	221.60 ± 2.40	40.180	<0.001
WEIGHT CHANGE	25.10 ± 3.70	27.20 ± 4.10	27.30 ± 3.90	27.50 ± 3.40	19.155	<0.001

(Mean ± SEM given for each measurement)

The final body weight for the experimental groups increased significantly ($P < 0.001$) relative to the control.

Morphometric Analysis of Organ (liver) Weight

Table 2: Comparison of mean relative liver weight of all the groups (A, B, C & D)

	GROUP A	GROUP B	GROUP C	GROUP D	F RATIO	PROB OF SIG
LIVER WEIGHT	5.10 ± 0.250	5.12 ± 0.310	5.13 ± 0.290	5.14 ± 0.340	50.40	<0.001

(Mean ± SEM given for each measurement)

The relative weights of the experimental groups increased significantly ($P < 0.001$) with the control A.

Histopathological Findings

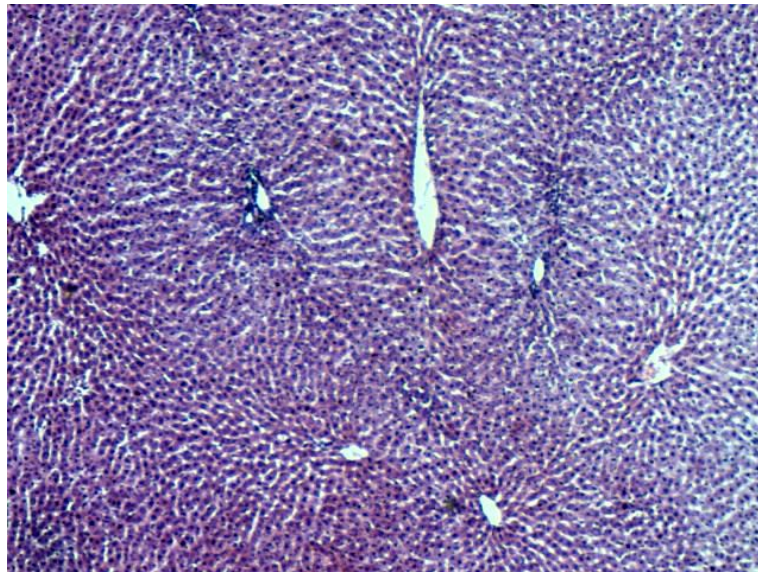


Fig 1. Micrograph 1, (control), shows normal histological structure of the liver, stained by H & E technique, x 200.

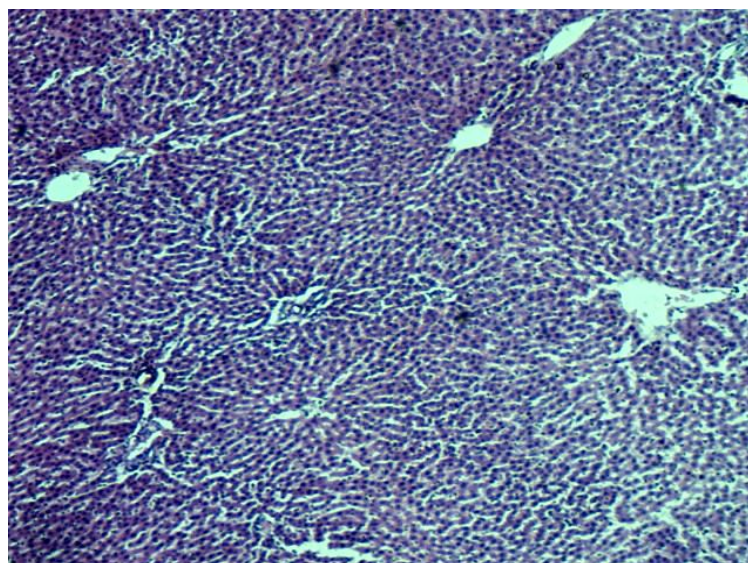


Fig 2. Micrograph 2, Group B, (treated with 0.55ml of *Aframomum melegueta* aqueous extract) showing non distortion of the hepatocytes, stained by H & E technique, x 200.

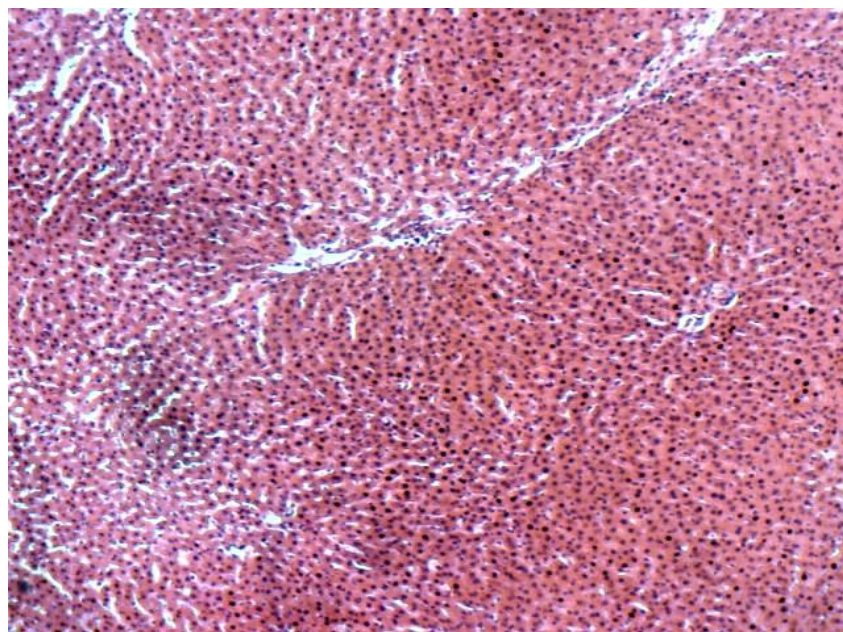


Fig 3. Micrograph 3, Group C, (treated with 0.65ml of *Aframomum melegueta* aqueous extract) shows normal morphology of the structure of the liver, stained by H & E technique, x 200.

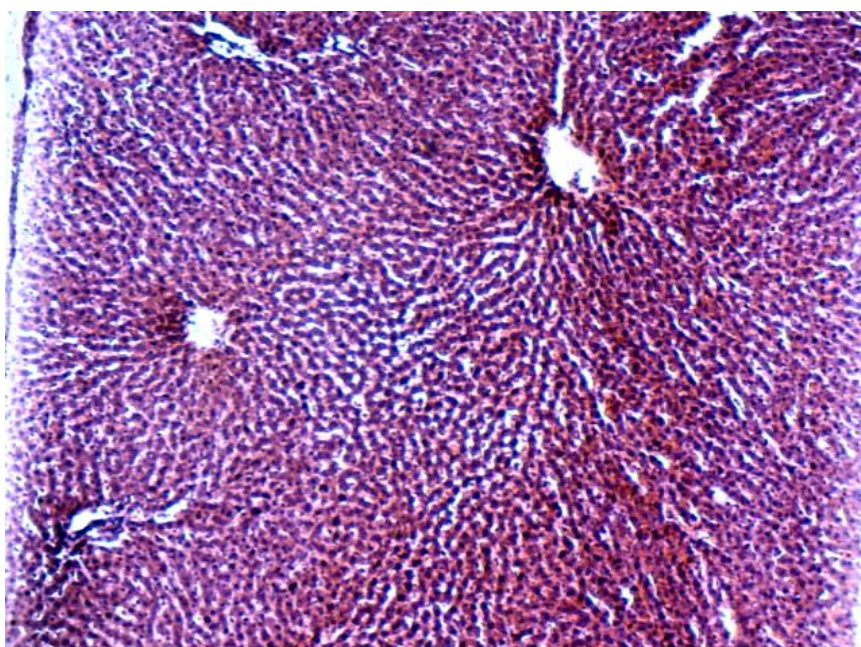


Fig 4. Micrograph 4, Group D, (treated with 0.75ml of *Aframomum melegueta* aqueous extract), showing normal histological structure of the liver, stained by H & E technique, x 200.

DISCUSSION

Aframomum melegueta extract has been shown to moderately inhibited acetylcholinesterase activity with IC_{50} of $373.33\mu\text{g/ml}^{12}$.

In the pancreas of rats treated with sodium nitroprussida (SNP) in vivo, *Aframomum melegueta* was noted to have concentration dependent protection of pancreatic β -cells thought to be through anti-oxidative properties¹².

In rats given a large amount of alcohol (4.8g/kg) for 15 days, co-ingestion of *Aframomum melegueta* (100-200mg/kg aqueous extract) noted that the higher dose was able to prevent an increase in liver weight and fully abolish lipid peroxidation as assessed by MDA while preserving both GSH and GST; hepatic superoxide dismutase (SOD) was not significantly influenced by *Aframomum melegueta* despite it being reduced with ethanol¹³.

In the present study, the body weight of the experimental groups increased significantly with the control. The organ (liver) weight of the experimental groups were similar with the control. Histological appearance of the liver cells showed non destruction of the liver cells in the experimental groups compared with the control.

CONCLUSION

From the present study, the aqueous extract of *Aframomum melegueta* has no toxic effects to the liver cells in low and high doses thus have protective properties.

REFERENCES

1. Ilic N, Barbara M, Schmidt, Alexandra P, Ilya R. Toxicological evaluation of grains of paradise (*Aframomum melegueta*)(Roscoe) K. Schum J. Ethnopharmacol, 2010; 127 (2): 352-6.
2. Gbolade A Ethnobotanical study of plants used in treating hypertension in Edo State of Nigeria. J. Ethnopharmacol. 2012; 31;144(1):1-10.
3. Ogbole OO, Ajaiyeoba EO Traditional management of tuberculosis in Ogun State of Nigeria: the practice and ethnobotanical survey Afr. J. Tradit. Complement Altern Med. 2009; 7:79-84.
4. Lans C, Harper T, Georges K, and Bridgewater E. Medicinal and ethnoveterinary remedies of hunters in Trinidad. BMC complement Altern. Med. 2001;1:10.
5. Van Andel T, Myren B, Van Onselen S Ghanas herbal market. J. Ethnopharmacol. 2012;140(2):368-78.
6. Konning GH, Agyare C, Ennison B Antimicrobial activity of some medicinal plants from Ghana. Fitoterapia.2004;75(1):65-7.
7. Ndamukong RJ et al Molluscicidal activity of some Cameronian plants on *Bulinus* species. East Afri Med. Journal. 8. Feb. 2014. Vol. 3, No.6
8. Ukel DA et al Repellant activity of alligator pepper, *Aframomum melegueta* and ginger, *zingiber officinale* against the maize weevil, *sitophilus zeamais*. Phytochemistry. 2009;23(3):21-26.
9. Ukeh DA et al Behavioural responses of the maize weevil, *sitophilus zeamais* to host (stored grain) and non host plant volatiles. Pest Management Sci. 2010; 67:1303-08.
10. Kamtchouing P, Mbongue GYF, Dimo T, Watcho P, Jatsa HB, Sokeng SD Effects of *Aframomum melegueta* and piper guineense on sexual behaviour of male rats Behav Pharmacol. 2002; 13:243-247.
11. Adefegha SA, Oboh G. Inhibition of keyenzymes linked to type 2 diabetes and sodium nitroprusside-induced lipid peroxidation in rats pancreas by water extractable phytochemicals from some tropical spices Pharm Biol. 2012; 31:144(1):1-10.
12. Adefegha SA, Oboh G. Acetylcholinesterase inhibitory activity, antioxidant properties and phenolic composition of two *Aframomum* species. J Basic Clin Physiol Pharmacol. 2012 23(4):153-61.
13. Nwozo SO, Onyinloye BE Hepatoprotective effects of aqueous extract of *Aframomum melegueta* on ethanol induced toxicity in rats. Acta Biochem Rol. 2011;46(4):451-8.