

**INTERNATIONAL JOURNAL OF ADVANCES IN  
PHARMACY, BIOLOGY AND CHEMISTRY****Research Article****Impact of Sugar cane peel (*Saccharum officinarum*)  
Extract on the Blood Status and Gonadal Integrity  
of Wistar Albino Rat**

<sup>1</sup>ASHADE, O.O., <sup>2</sup>ABUBAKAR, R.O., <sup>2</sup>NGUKA, O.O., <sup>2</sup>YAKUBU, A.O., <sup>2</sup>OYESANYA,  
O., <sup>2</sup>OFOEGBU, C.C., <sup>2</sup>BELLO, O.N., <sup>2</sup>OSUNTADE, B.A.

<sup>1</sup>Department of Biological Science, Yaba College of Technology, Yaba, Lagos, Nigeria.

<sup>2</sup>Department of Chemical Science, Yaba College of Technology, Yaba, Lagos, Nigeria.

**ABSTRACT**

Sugar cane extract is a natural product which has played a wide range biological effects including thrombosis and anti-inflammatory activities. Sugarcane peel is a renewable raw material rich in different molecular species of antioxidants, an agro-waste product and contains considerable amount of wax. The study was carried out to evaluate the effects of ethanolic extract of *Saccharum officinarum* peel on haematological and histopathological parameters. The study assessed total packed cell volume, haemoglobin, platelet, white blood cells, and the red blood cells for haematological indices and testes and ovaries for histopathology. A total number of eighty Wistar albino rats weighing (145g-206g) was used for this study and rats were divided into four groups of four (4) rats each for both sex. Group A served as control and was treated with distilled water and feed of treatment equivalence, B, C and D were treated with various concentration of the extract as follows; 0.5ml/125mg/kg, 0.5ml/500mg/kg, 0.5ml/1000mg/kg, for male and female rats. Grouping was done in triplicate for groups B, C and D. The administration of the extract lasted for twenty one (21) days period, after which the animals were sacrificed and blood samples were for haematological study and organs; ovaries and testes for histopathological analysis. Results revealed that *Saccharum officinarum* peel ethanolic extract treatment caused reduction in the body weights ( $p < 0.05$ ), packed cell volume, white blood cells, platelet, red blood cells, haemoglobin and proliferation of ovarian tissues compared with the control. Testes, however showed no pathological integrity profile. The study suggested that *Saccharum officinarum* peel ethanolic extract causes mild decline in the immune system and exert cellular stress on the ovary which could lead to irregular egg production.

**Keywords:** Haematology, histopathology, *Saccharum officinarum* (sugar cane) peel.

**INTRODUCTION**

Nature has been considered as a source of medicinal agents from the ancient drugs have been isolated is mainly based on the traditional use of these plants in treatment of disease. This plant base, traditional medicine system still acquires an important place in the health care system. Today medicinal plants are used on functional and health food and still acquire an important place in the health care industries. Fertility control is an issue of global and national health concern. Fertility regulation

comprising contraception and management of infertility forms an important component of reproduction health<sup>1</sup>. Sugar cane belongs to the grass family (*poaceae*), an economically important seed plant family that includes maize, wheat, rice and sorghum and many image crops. The main product of sugar cane is sucrose, which accumulates in the stalk internodes. Sugar cane peel extract is natural product which has displayed a wide range of biological effects including immunologiation and thrombosis

activity chlorine release and anti-stress effects. Sugar cane peel is a renewable raw material which in different molecular species of antioxidants and an agro-waste product and contains considerable amount of wax<sup>2</sup>. Sugar cane (*Saccharum officinarum*) is a widely source not only for sugar and raw materials for alcoholic production, but also for a variety of other products. Sugar cane peel extract often contain potent polyphenolic antioxidant such as anthocyanin and Tannins<sup>3</sup>. Sugar cane (*Saccharum officinarum*) peel is one of the industrially important crops mainly in Brazil and India, sugar cane is one of the world most important sugar crops providing over 46% of sugar for human consumption<sup>4</sup>. This present study is to determine the histopathological (testes and ovary) and Haematological (PCV, RBC, PLT, WBC, Hb) effects of *Saccharum officinarum* (sugar cane) peel ethanolic extract on albino rat.

#### METHODOLOGY

Material: *Saccharum officinarum* (sugar cane) peel, 80% ethanol, Muslin cloth, beaker, EDTA bottles, Sample bottles, slides and capillary tubes.

#### COLLECTION OF SUGAR CANE PEEL

The sugar cane peel were collected from the sugar cane depot at Idi-araba, Lagos state Nigeria. The plant was identified and authenticated at the biochemistry department of the College of Medicine, University of Lagos, Nigeria.

#### METHOD OF EXTRACTION

The *Saccharum officinarum* (sugar cane) peel were collected, cut into smaller pieces and oven dried at 70<sup>0</sup>c till complete dryness. The dried peel were grounded to fine powder and mixed with 80% ethanol and soaked for 3days. It was then filtered with a clean muslin cloth, the filtrate was collected in a beaker and kept in the oven, and the ethanol was allowed to evaporate to yield 86.3g of the extract. The concentration was dissolved in distilled water for the purpose of this study.

#### PHYTOCHEMICAL SCREENING

*Saccharum officinarum* (sugar cane) peel extract was examined using method developed by Norman (1966)<sup>5</sup> for the presence of the following phytochemical constituents; Tannins, Phlobatannin, Flavonoid, Saponin, Cardiac glycosides, Steroids, Alkaloids, Terpenoids and sugar presence in the extract.

#### EXPERIMENTAL ANIMALS

A total number of eighty (80) mature and healthy males and females albino rats weighing (145g-206g)

were obtained from the animal house in the College of Medicine of the University of Lagos, Idi-araba, they were housed in clean plastic cages, well ventilated in 12 hours light and 12 hours dark cycle respectively. Animals were provided with pelleted rat chow and clean water and acclimatized for 2weeks before administration commenced. The aqueous extract was administered for twenty one (21) days and fasted overnight and the body weight of the animals was also taken before sacrificing them.

#### Grouping for Experimentation

Group A: control (8 albino rats)

Group B: 0.5ml of 125mg/kg sugarcane extract given to rats (4 males, 4 females in triplicate) using mice canula

Group C: 0.5ml of 500mg/kg sugar cane extracts given to rats (4 males, 4 females in triplicate) using mice canula

Group D: 0.5ml of 1000mg/kg sugar cane extracts given to rats (4 males, 4 females in triplicate) using mice canula

#### BLOOD COLLECTION FOR HAEMATOLOGICAL ASSAY

Blood was collected through the eye of each animal with the help of a capillary tube. About 1ml of blood was dispensed into Ethylene Diamine Tetra-acetic acid (EDTA) bottles containing anticoagulant to prevent the blood from clotting so as to give a good result on haematological assay. The blood with EDTA was used for the count of RBC, differential and total count of WBC and platelet by standard procedures<sup>6</sup>.

#### COLLECTION OF ORGANS FOR HISTOPATHOLOGICAL ASSAY

The method adopted by Momoh et al.,<sup>7</sup> was used. The reproductive organs (ovary and testes) were collected from each animal and preserved in 10% formal saline in the specimen bottles.

#### REGISTRATION OF TISSUE FOR HISTOPATHOLOGICAL ASSAY

Registration of the tissue was done according to the nature of the tissue, laboratory number and the research topic.

**Cut-up:-** The samples were cut and placed inside a well labeled tissue embedding cassette.

**Processing:-** The tissue were then processed using a 24 hours automatic tissue processor for a time ranging from 17-19 hours depending on the tissue type to be processed. The tissue processor containing 12 beakers; 10 glass beaker and 2 thermostatically

controlled electric metal beakers containing paraffin wax.

#### BEAKER CONTENT

**Beaker 1:-** This contains 10% formal saline for complete fixation.

**Beaker 20-8:-** Contains different ascending grades of dehydrating fluids (alcohol ranging from 70% alcohol to absolute alcohol (isopropyl alcohol). This help to remove water from the tissue samples.

**Beaker 9-10:-** Contains cleaning agent (xylene I and II) which completely clears dehydrating agent off the tissue sample.

**Beaker 11-12:-** Contains embedding agent, that is, molten paraffin wax which provides solid support upon embedding.

#### EMBEDDING

The tissue after been processed was embedded using an automatic embedding centre. Embedding is a process of submerging a tissue in a metal/plastic disposable embedding mould containing molten paraffin wax. The paraffin wax becomes solidified when it get cold. This form is a support medium for the tissue during sectioning.

#### MICROTOMY

Sections of the tissues were cut using a microtome (model 1810). The sections were cut and placed in a clean grease free slide which was then placed on a hot plate for 30minutes in order for section to adhere to the slide.

#### STAINING METHOD

The staining method used was the H & E staining method<sup>8</sup>. This method was used because it is used to demonstrate the general structure of tissue.

#### PROCEDURE

Tissue were dewaxed in xylene. The sections were taken to water by using descending grades alcohol, that is, from absolute alcohol  $\geq 95\%$  alcohol  $\geq 70\%$  alcohol  $\geq$  water and was stained in haematoxylin for 10minutes, and then rinsed in water, then differentiated in 1% acidic alcohol (a dip) and rinsed in water again, and was blue in tap water for 5 minutes. It was also counter stained in 1% Eosin for 2-5 minutes. It was then rinsed in tap water and dehydrated using ascending grades alcohol, (70%alcohol  $\geq 95\%$  alcohol  $\geq$  absolute alcohol). It was then cleared in xylene and mounted using D.P.X. And lastly was viewed under the microscope to get the result.

#### STATISTICAL ANALYSIS

Results are expressed as the mean  $\pm$  SD. Statistical significance was evaluated by ANOVA using SPSS

10. A value of  $p < 0.05$  was considered to indicate difference between parameters.

#### RESULTS

*Saccharum officinarum* (Sugar cane) peel extract was examined for the presence of the following phytochemical constituents; Tannins, Phlobatannin, Flavonoids, Saponin, Cardiac glycosides, Steriod, Alkaloids, Terpenoids and sugar presence in the extract.

#### HAEMATOLOGICAL RESULT IN MALE

White blood cells count reduced from  $10.16 \pm 0.16$  (control) to  $4.73 \pm 0.38$  (1000mg/kg). Great reduction was also observed in PCV level; from  $57.30 \pm 0.40$  in control to  $1.93 \pm 0.36$  (1000mg/kg). Steady decline in haemoglobin and RBC were observed too. Alternate platelet levels observed as well (Table 2) and figure 1 – 4.

#### HAEMATOLOGICAL RESULTS IN FEMALE

There was wide margined difference between the PCV in control rat and rat dosed with 1000mg/kg. ( $50.30 \pm 0.20$  as against  $4.37 \pm 0.15$ ) as seen in table 3. Haemoglobin levels declined with increased dosage. ( $14.27 \pm 0.25$  to  $2.90 \pm 0.20$ ). Reduction in RBC counts also recorded from  $7.97 \pm 0.32$  in control to  $0.65 \pm 0.03$  in rats with 1000mg/kg extract (fig. 1 – 4).

#### HISTOPATHOLOGY RESULT IN MALE

The control (testes) shows normal appearance of spermatogenic series within the seminiferous tubules (fig. 6). Fig. 7 – 9 showed same status as seen in the control plate through concentration ranged from 125mg/kg to 1000mg/kg.

#### HISTOPATHOLOGY RESULT IN FEMALE

The control (ovary) showed normal appearing ovarian follicle and stroma (fig. 10). Also at 125mg/kg extract dosage, same was observed as control (fig. 11). Mild atretic ovarian follicle with loose ovarian stroma was observed in 500mg/kg extract dosage (fig. 12). However at 1000mg/kg extract dosage concentration, marked atretic ovarian follicle with loose ovarian stroma was observed (fig. 13).

#### The histopathological analysis of the study are seen in figures 6-13

#### DISUSSION

The administration of ethanolic extract of *Saccharum officinarum* peel suggested that the extract contains some phytochemical constituents such as alkaloids, saponins, tannins, phlobatannin, cardiac glycosides and terpenoids. Steroids was however absent (Table

1). Presence of these quenchers of free radicals extensively confirms its antimicrobial analgesic and anti-inflammatory potential. Worthy of note is the poisoning action of saponin<sup>9</sup>. There was body weight fluctuation as concentration of extracts increased in both sexes (Tables 4 and 5). The haematological parameters which are the white blood cells, packed cell volume, platelets and haemoglobin were found to decline though marginally against control values, but significantly different ( $p < 0.05$ ) with varied peel extracts in both male and female Wistar albino rats (Tables 2 and 3). This was corroborated by Bolarinwa et al.,<sup>10</sup> on the study of *Tatrophacurcus* extract. Altered white blood cells (lymphocytes, and neutrophils) and platelets count was explained that the plant extract would have some mild effect on the haematological parameters. Other reasons could be dose level and individual variation of rats as given in Swenson and Reece<sup>11</sup>.

On the basis of the histopathological studies of the testes and ovaries, the integrity of the testes were relatively intact (fig 7 – 9) with shrunk size. This

weight loss was attributed to lower bioavailability of androgen as stimulated by the extract. Adverse effects of the extract on the ovary as evidenced in remarkable atretic ovarian follicle with loose ovarian stroma formation (fig 11-13) can result from reduced gonadotropin secretion, impairment of follicular growth, or enzymatic interference, resulting in a reduction of sex steroid hormone<sup>12</sup>. The net effect is reduced folliculogenesis.

Conclusively, the administration of *S. officinarum* peel extract resulted into relative decrease in blood count and increased degeneration of follicles before maturity, especially at high dose level. In other words, dysfunctional ovary pre-puberty could manifest with a resultant effect on fertility status. It could be reasoned that lengthy exposure with regards to spermatogenic cycle and increased concentration to this extract may result into morphological and physiological testicular aberration. More research is therefore recommended in this regard.

**Table 1**  
**Phytochemical result**

PHYTOCHEMICAL CONSTITUENTS	SUGAR CANE PEEL EXTRACT
Tannins	+
Phlobatannin	+
Flavonoids	+
Saponin	+
Cardiac glycosides	+
Steroids	-
Terpenoids	+
Sugar	+

KEY: + present – absent

**Table 2**  
**Haematological parameters of males treated with the aqueous extract of *S. officinarum***  
**Analysis result for male**

Groups	Sample	White Blood Cell (WBC) X 10 <sup>9</sup>	Packed Cell Volume (PCV)%	Haemoglobin (Hb) g/dl	Red Blood Cell (RBC) X10 <sup>12</sup>	Platelet (PLT) x 10 <sup>9</sup>
A	Control	10.06±0.16	57.30±0.40	16.20±0.30	9.47±0.25	721.00±7.00
B	125mg/kg	8.50±0.20*	43.40±0.20*	13.03±0.15*	7.50±0.20*	561.33±4.16*
C	500mg/kg	8.67±0.25*	45.40±0.30*	12.07±0.25*	7.60±0.20*	649.00±2.00*
D	1000mg/kg	4.73±0.38*	1.93±0.15*	10.90±0.36*	0.25±0.03*	586.67±4.51*

Note: α = Level of significance (0.05 or 5%).

Values represent the Means ± SEM, n=3. The values with asterisk are significantly different from the control @ p-value < 0.05.

**Table 3**  
**Haematological parameters of females treated with the aqueous extract of *S. officinarum***  
**Statistical Analysis for female**

Sample	White Blood Cell (WBC) X 10 <sup>9</sup>	Packed Cell Volume (PCV)%	Haemoglobin (Hb) g/dl	Red Blood Cell (RBC) 10 <sup>12</sup>	Platelet (PLT) x 10 <sup>9</sup>
Group A (control)	6.49±0.21	50.30±0.20	14.27±0.25	7.97±0.32	586.33±7.02
Group B (125mg/kg)	5.79±0.26*	46.43±0.25*	12.23±0.15*	7.95±0.02*	1008.00±3.00*
Group C (500mg/kg)	8.67±0.30*	45.40±0.25*	12.07±0.20*	7.60±0.02*	649.00±3.61*
Group D (1000mg/kg)	3.20±0.20*	4.37±0.15*	2.90±0.20*	0.65±0.03*	1693.33±5.51*

Note:  $\alpha$  = Level of significance (0.05 or 5%).

Values represent the Means  $\pm$  SEM, n=3. The values with asterisk are significantly different from the control @ p-value < 0.05.

**Table 4**  
**Statistical analysis for female body weight before and after treatment**

Sample	Week1	Week2	Week3
Group A (control)	200.67±6.11*	191.33±1.53*	196.00±6.24*
Group B (125mg/kg)	196.67±7.77*	194.00±4.00*	201.67±2.08*
Group C (500mg/kg)	190.33±1.53*	189.00±3.00*	202.67±4.16*
Group D (1000mg/kg)	181.67±4.04*	177.00±3.00*	193.67±4.73*

Note:  $\alpha$  = Level of significance (0.05 or 5%).

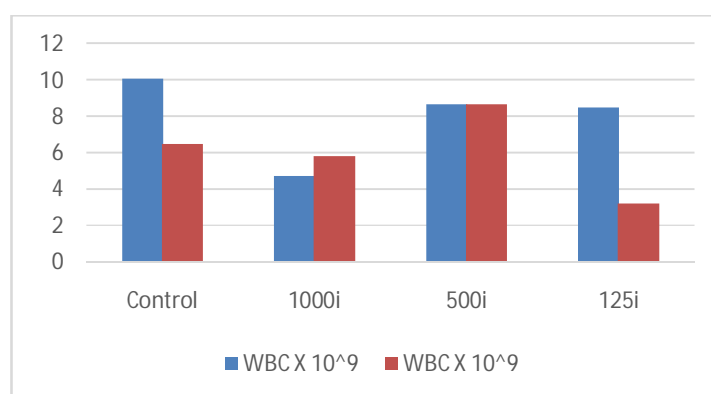
Values represent the Means  $\pm$  SEM, n=3. The values with asterisk are significantly different from the control @ p-value < 0.05.

**Table 5**  
**Statistical analysis for male weight**

Sample	Week1	Week2	Week3
Group A (control)	150.33±5.03*	171.00±4.00*	159.00±3.00*
Group B(125mg/kg)	145.67±3.06*	159.00±6.56*	154.00±3.00*
Group C (500mg/kg)	157.33±4.04*	146.33±3.06*	151.00±2.00*
Group D (1000mg/kg)	128.00±2.00*	104.67±3.51*	121.67±3.51*

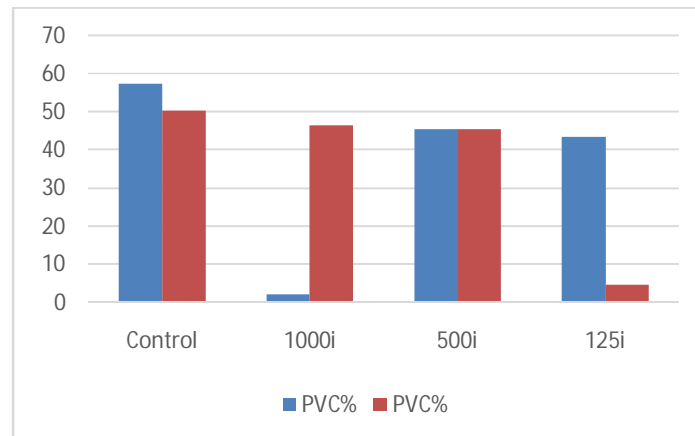
Note:  $\alpha$  = Level of significance (0.05 or 5%).

Values represent the Means  $\pm$  SEM, n=3. The values with asterisk are significantly different from the control @ p-value < 0.05.



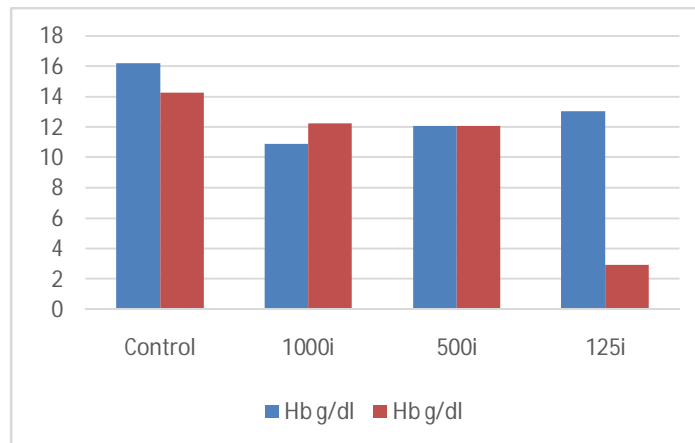
**Fig 1**

The plot of control and parameter WBC at different level of concentrations for both male and female.



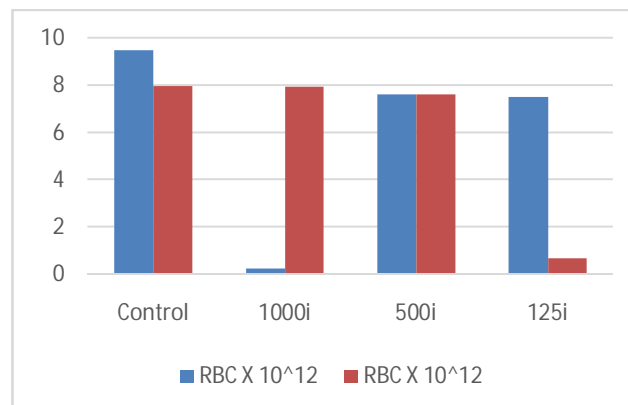
**Fig 2**

The plot of control and parameter PCV at different level of concentrations for both male and female.



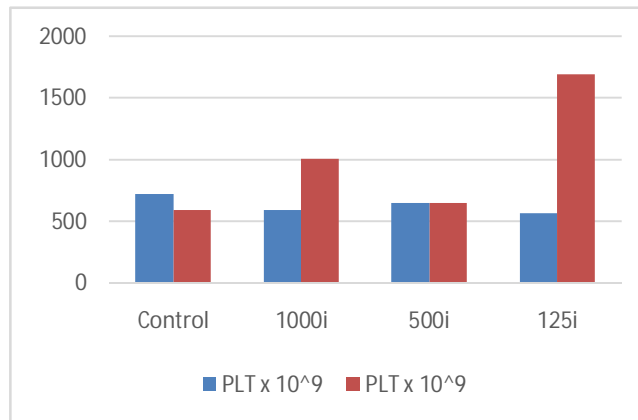
**Fig 3**

The plot of control and parameter Hbg/dl at different level of concentrations for both male and female.



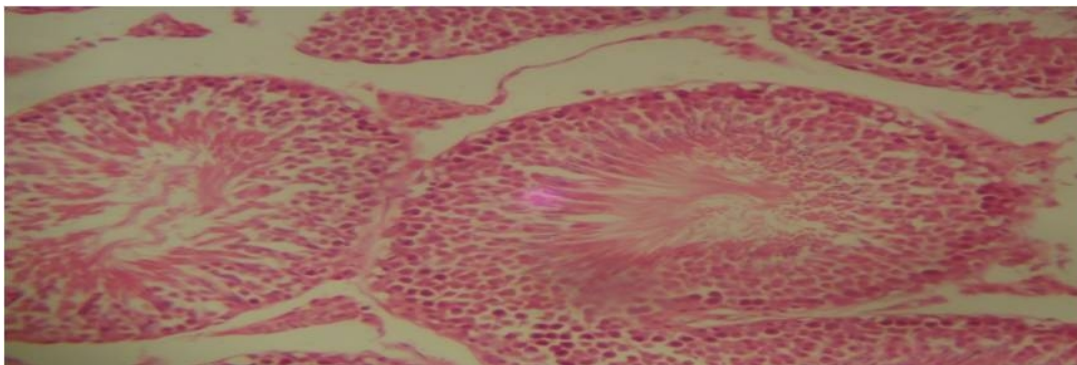
**Fig 4**

The plot of control and parameter RBC at different level of concentrations for both male and female.



**Fig 5**

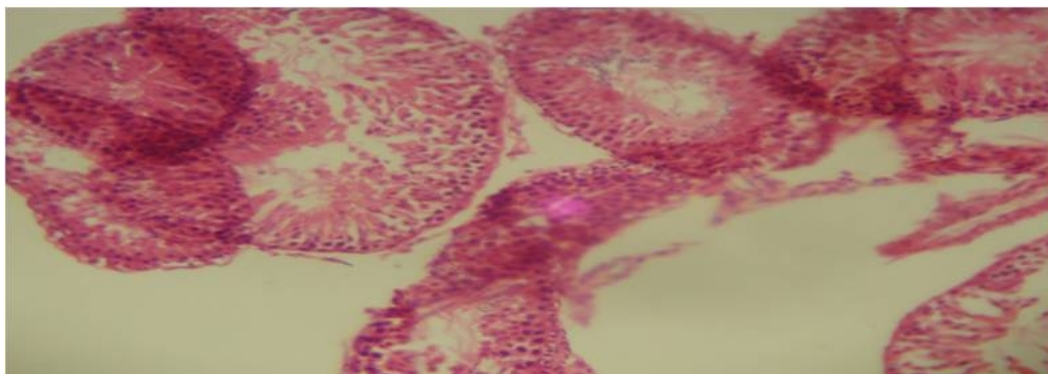
The plot of control and parameter PLT at different level of concentrations for both male and female.



**Fig 6**

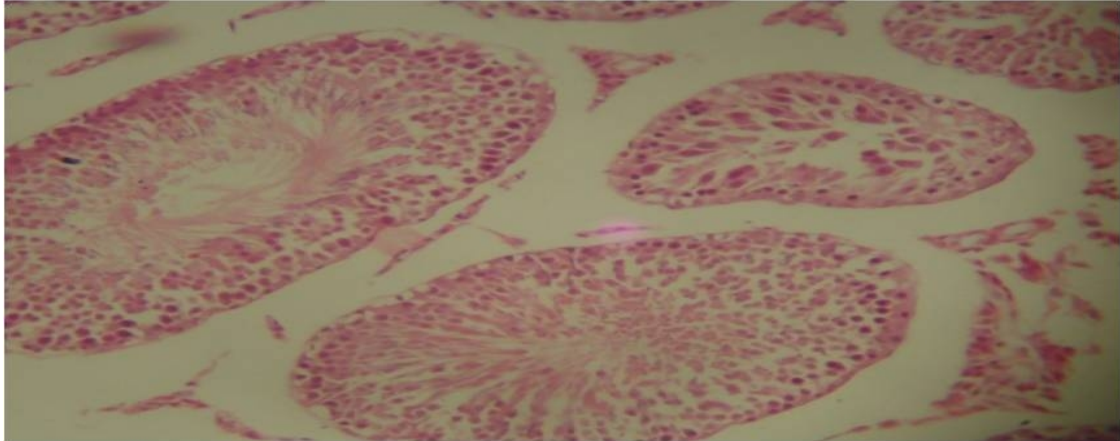
Control of testes

Histopathological effect on males treated with *S. officinarum* peel extract Control testes

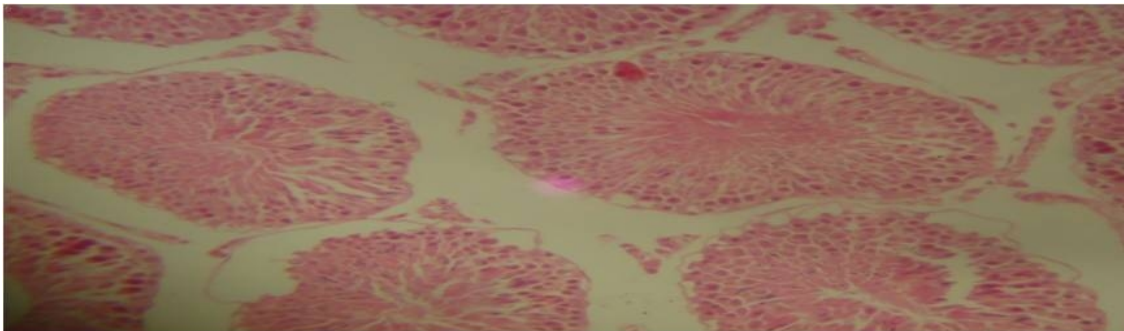


**Fig 7**

0.5ml/125mg/kg of sugar cane peel extract on testes.

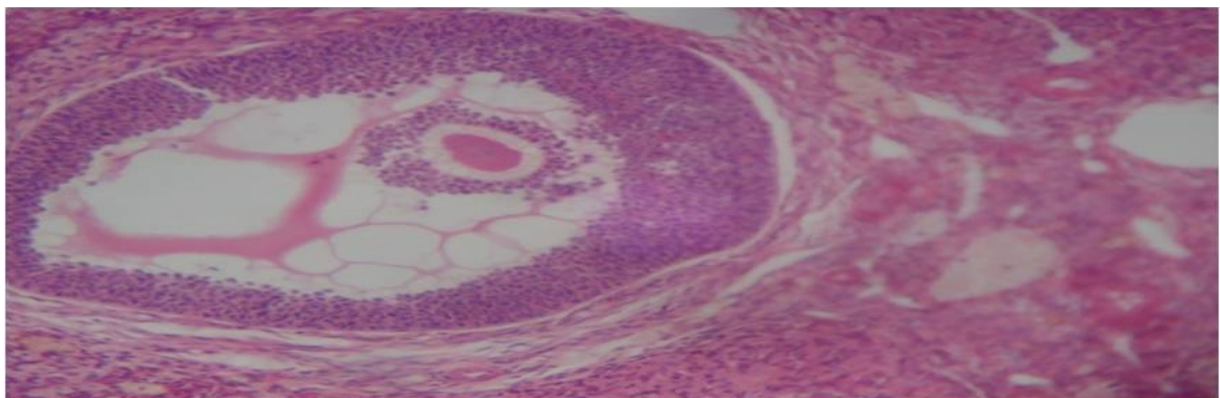


**Fig 8**  
0.5ml/500mg/kg of sugar cane peel extract on testes.



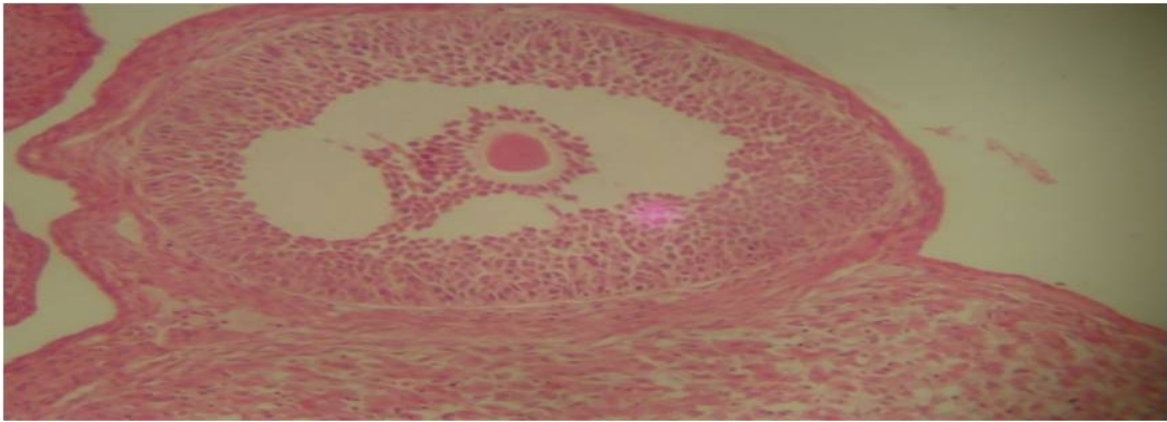
**Fig 9**  
0.5ml/1000mg/kg of sugar cane peel extract on testes.

**Histopathological effect on females (ovary) treated with *S. officinarum* peel extract**

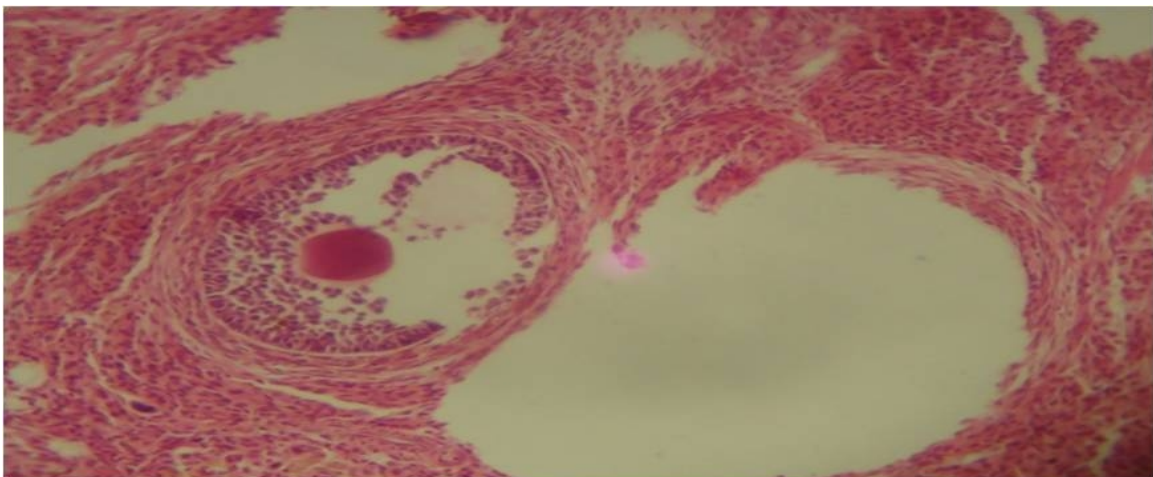


**Fig 10**  
Control of ovary

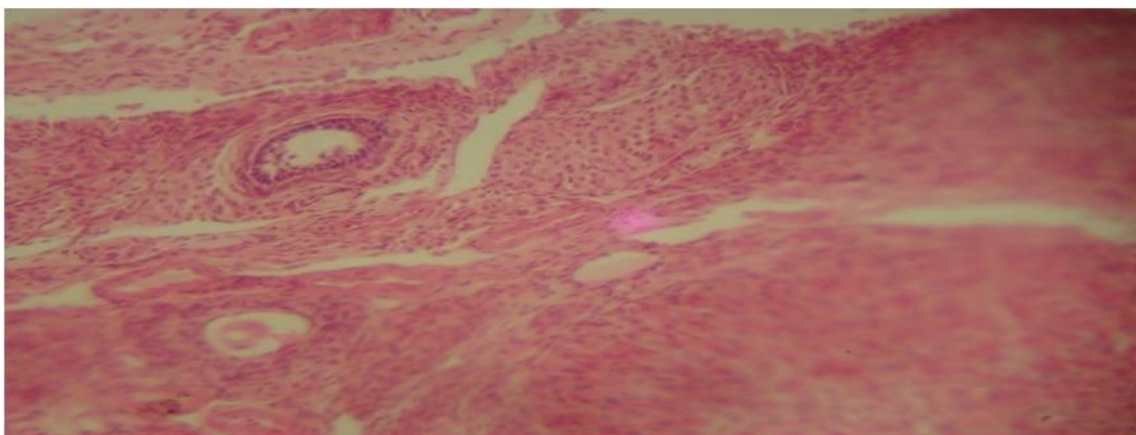




**Fig 11**  
**0.5ml/125mg/kg of sugar cane peel extract on ovary**



**Fig 12**  
**0.5ml/500mg/kg of sugar cane peel extract on ovary.**



**Fig 13**  
**0.5ml/1000mg/kg of sugar cane peel extract on ovary.**

## REFERENCES

1. Arvind Singh and Sushila Kala 2011. Duration dependent effect of plants extract on haematology, Histopathology Hormonal profile and sperm parameters of rats; An approach for male contraceptive development. Double Helix in Pharmaceutical Research. 1(1).
2. Pallavi R, Elakkiya S, Tennety SSR. and Devi PS. Anthocyanin analysis and its anticancer property from sugar cane (*Saccharum officinarum*) peel. International Journal of Research in Pharmacy and Chemistry. 2012;2(2)338-345.
3. Wang SY, Hsu, MLHC, Tzeng CH, Lee SS, Shiao Ms, Ho CK 1997. The anti-tumor effect of *Ganoderma lucidum* is mediated by Cytokines released from activated macrophages and T lymphocytes Int. J. Cancer 70:699-705.
4. Hemlatha S, Elakkiya, Tennety SSR, and Suganya Devi P, Pallavi R. Anthocyanin Analysis and its Anticancer property From Sugarcane (*Saccharum officinarum*) peel. International Journal of Research in Pharmacy and Chemistry, 2012;2(2)338-345.
5. Norman RF. Biological and Phytochemical screening of plants. Journal of Pharmaceutical Sciences 1966; (55):275–276.
6. Sanderson, J.H. and Philips, C.E. 1981. An atlas of laboratory animal haematology. Oxford University press: New York. P.471
7. Momoh AO, Oladunmoye MK and Adebolu TT. Haematology and Histopathology effects of oil castor seeds (*Ricinus communis* LNN) on Albino rats. Journal of Pharmacognosy and Phytotherapy. 2012;4(4):40-43.
8. Fadina OO, Taiwo VO. and Ogunsanmi AO. Single and repetitive oral administration of common pesticides and alcohol on rabbits. Trop. Vet. 1999;17, 97-106.
9. Shumaik GA, WU AW, Ping AC. Oleander Poisoning: Treatment with digoxin-specific Fab antibody fragment. Ann. Emerg. Med. 1988;17:732-735.
10. Bolarinwa AF and Oluwole. *Jatropha curcus* causes anaemia in Rats. Phytother Res. 1997;11:538-539.
11. Swenson M. and Reece J.W.O 1993. Duke physiology of domestic animals. 11<sup>th</sup> ed. Comstock publishing Associates, Ithaca, New York, U.S.A.
12. Ratcliffe, J.M., McElhatton, P.R. and Sullivan, F.M. Reproductive toxicity 1995. In: Ballantyne B, Marrs T, Turner p, editors. General and Applied Toxicology, London: Macmillan Press Ltd. Pp925 – 956.