

INTERNATIONAL JOURNAL OF ADVANCES IN PHARMACY, BIOLOGY AND CHEMISTRY

Review Article

Onychomycosis and Its Treatment

Amartya De, NN. Bala and Abu Taher

B.C.D.A College of Pharmacy & Technology, 78, Jessore Road(S), Hridayapur, Barasat, Kolkata, West Bengal, India.

ABSTRACT

Onychomycosis is a very common problem affected many people more much in rural area. This condition may affect toenails or fingernails, but toenail infections are particularly common. In this article we discuss about etiology, pathophysiology, prevention and treatment of the disease.

Keywords: Onychomycosis, subungual onychomycosis, candidiasis, Laser Treatment.

INTRODUCTION

Onychomycosis (also known as "dermatophytic onychomycosis," "ringworm of the nail," and "tinea unguium")¹ means fungal infection of the nail². It is the most common disease of the nails and constitutes about a half of all nail abnormalities³.

This condition may affect toenails or fingernails, but toenail infections are particularly common. The prevalence of onychomycosis is about 6-8% in the adult population⁴.

CLASSIFICATION OF ONYCHOMYCOSIS

Four types of onychomycosis, characterized according to clinical presentation and the route of invasion, are recognized.

i. Distal Subungual Onychomycosis

Distal subungual onychomycosis (DSO) is the most common form of onychomycosis. It is characterized by invasion of the nail bed and underside of the nail plate beginning at the hyponychium. The infecting organism migrates proximally through the underlying nail matrix. Mild inflammation develops, resulting in focal parakeratosis and subungual hyperkeratosis, with two consequences: onycholysis (detachment of the nail plate from the nail bed) and thickening of the subungual region. This subungual space then can serve as a reservoir for superinfecting bacteria and molds, giving the nail plate a yellowish brown appearance.

DSO is usually caused by the dermatophyte *T. rubrum* (although *T. mentagrophytes*, *T. tonsurans*, and *E. floccosum* also are known to be causative. DSO may develop on the fingernails, toenails, or both, with infection of the toenails being much more common than infection of the fingernails; in

the Finnish study, only 2 of the 91 patients with dermatophyte-related onychomycosis of the toenails also had fingernail involvement. Toenail infections were approximately 20 times more common than fingernail infections in the Ohio cohort. The increased frequency of toenail in comparison to fingernail infections probably reflects the greater incidence of tinea pedis than of tinea manuum⁵.

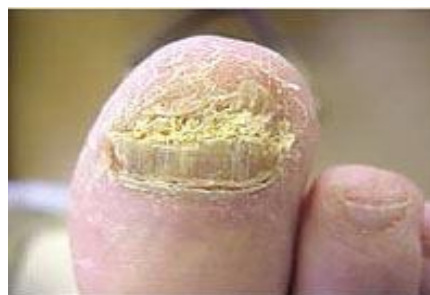

Fig: Distal subungual onychomycosis.

ii. Proximal Subungual Onychomycosis

Proximal subungual onychomycosis (PSO) is also known as proximal white subungual onychomycosis (PWSO), a relatively uncommon subtype, and occurs when organisms invade the nail unit via the proximal nail fold through the cuticle area, penetrate the newly formed nail plate, and migrate distally. The clinical presentation includes subungual hyperkeratosis, proximal onycholysis, leukonychia, and destruction of the proximal nail plate. In the United States *T. rubrum* is the principal causative agent of PSO.

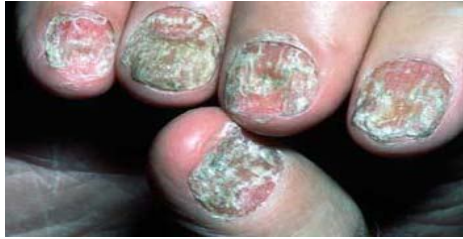

Fig: Proximal subungual onychomycosis.

The pattern of growth in PSO is from the proximal nail fold on the lunula area distally to involve all layers of the nail. Although PSO is the most infrequently occurring form of onychomycosis in the general population, it is common in AIDS patients and is considered an early clinical marker of HIV infection. (In one study of 62 patients with AIDS or AIDS-related complex and onychomycosis, 54 patients (88.7%) had PSO, with *T. rubrum* being the etiologic agent in more than half of these patients. In 54 patients, the feet were affected, and in 5 patients, the hands were infected; infections of both toenails and fingernails were present in 3 patients⁶. Infection may also occasionally arise secondary to trauma.

iii. White Superficial Onychomycosis

White superficial onychomycosis (WSO) is less common than DSO (estimated proportion of onychomycosis cases, 10%) and occurs when certain fungi invade the superficial layers of the nail plate directly. (Later, the infection may move through the nail plate to infect the cornified layer of the nail bed and hyponychium.) It can be recognized by the presence of well-delineated opaque “white islands” on the external nail plate, which coalesce and spread as the disease progresses. At this point, the nail becomes rough, soft, and crumbly. Inflammation is usually minimal in patients with WSO, because viable tissue is not involved (WSO) occurs primarily in the toenails.

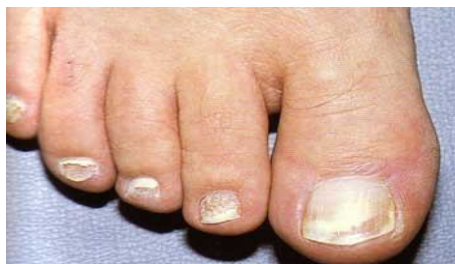

Fig: White superficial onychomycosis

The most common etiologic agent in WSO is *T. mentagrophytes*. In addition, several nondermatophyte molds, including *Aspergillus terreus*, *Acremonium roseogrisum* (later confirmed to be *Acremonium potronii*), and *Fusarium oxysporum*, have been implicated by Zaias et al.⁷

iv. Candida Infections of the Nail

Candida nail infections occur in patients with chronic mucocutaneous candidiasis, and are caused by *C. albicans*. The organism invades the entire nail plate. *Candida* spp. may cause other syndromes, including onycholysis and paronychia. These forms occur more commonly in women than in men and often affect the middle finger, which may come into contact with *Candida* organisms that reside in the intestine or vagina. *Candida* onychomycosis can therefore be divided into three general categories.

(i) Infection beginning as a paronychia (infection of the structures surrounding the nail; also called a “whitlow”), the most common type of *Candida* onychomycosis, first appears as an edematous, reddened pad surrounding the nail plate. Invasion by *Candida* spp., unlike dermatophytic invasion, penetrates the nail plate only secondarily after it has attacked the soft tissue around the nail. After infection of the nail matrix occurs, transverse depressions (Beau’s lines) may appear in the nail plate, which becomes convex, irregular, and rough and, ultimately, dystrophic.

(ii) Patients with chronic mucocutaneous candidiasis are at risk for the second type of, called *Candida* granuloma, which accounts for fewer than 1% of onychomycosis cases. This condition is seen in immunocompromised patients and involves direct invasion of the nail plate. The organism invades the nail plate directly and may affect the entire thickness of the nail, resulting, in advanced cases, in swelling of the proximal and lateral nail folds until the digit develops a pseudo-clubbing or “chicken drumstick” appearance.⁸

(iii) Finally, *Candida* onycholysis can occur when the nail plate has separated from the nail bed. This form is more common on the hands than the feet. Distal subungual hyperkeratosis can be seen as a yellowish gray mass lifts off the nail plate. The lesion resembles that seen in patients with DSO.

v. Total Dystrophic Onychomycosis

Total dystrophic onychomycosis is used to describe end-stage nail disease, although some clinicians consider it a distinct subtype. It may be the end result of any of the four main patterns of onychomycosis. The entire nail unit becomes thick and dystrophic.⁹

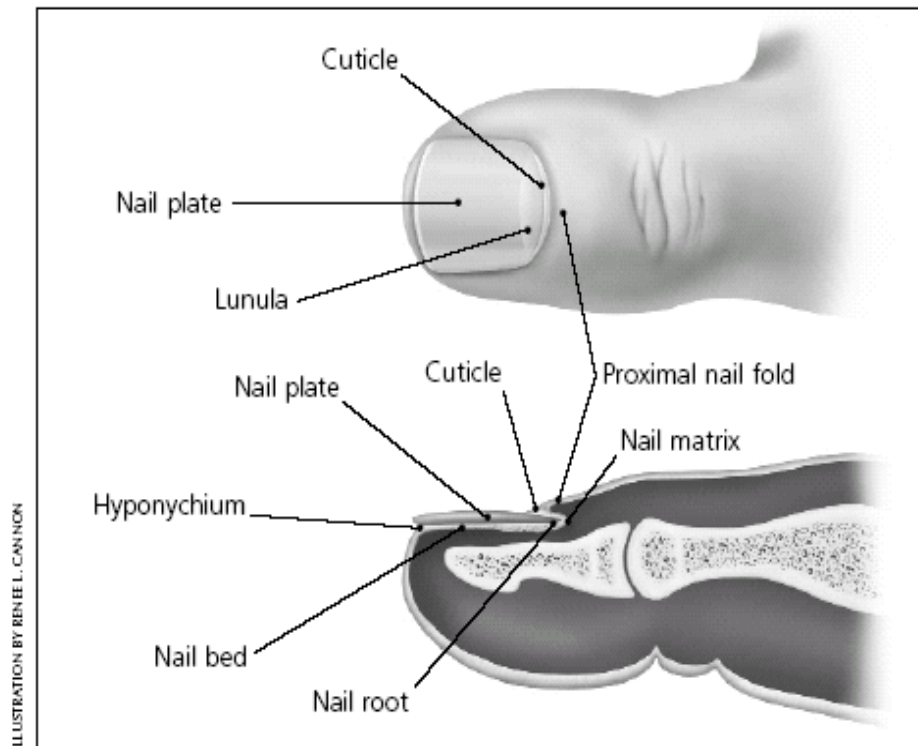
ANATOMY OF THE NAIL

To have a better understanding of how onychomycosis affects the nail, a general knowledge of the anatomy of the nail is helpful. The nail, or nail unit, consists of the following parts:

- The nail matrix (where the nail starts) is where nail cells multiply and keratinize (harden and form into nail material) before being incorporated into the fingernail or

toenail. Most of the matrix is not visible. The matrix starts under the skin 5 mm below the nail fold (the area of the cuticle where the finger or toe skin meets the nail) and covers the area called the lunula, or half moon (the white half moon-shaped area at the bottom of the nail).

- The cuticle is a fold of modified skin where the finger or toe meets the nail. The cuticle protects the matrix from infection.
- The nail plate is the nail itself.
- The nail bed is the soft tissue underneath the nail, anchoring the nail plate. The nail plate protects the nail bed.⁹



CAUSES OF ONYCHOMYCOSIS

Onychomycosis is caused by three main classes of organisms: dermatophytes (fungi that infect hair, skin, and nails and feed on nail tissue), yeasts, and nondermatophyte molds. All three classes cause the very similar early and chronic symptoms or appearances, so the visual appearance of the infection may not reveal which class is responsible for the infection. Dermatophytes (including *Epidermophyton*, *Microsporum*, and *Trichophyton* species) are, by far, the most common causes of onychomycosis worldwide. Yeasts cause 8% of cases, and nondermatophyte molds cause 2% of onychomycosis cases.

- The dermatophyte *Trichophyton rubrum* is the most common fungus causing distal lateral subungual onychomycosis (DLSO) and proximal subungual onychomycosis (PSO).
- The dermatophyte *Trichophyton mentagrophytes* commonly causes white superficial onychomycosis (WSO), and

more rarely, WSO can be caused by species of nondermatophyte molds.

- The yeast *Candida albicans* is the most common cause of chronic mucocutaneous candidiasis (disease of mucous membrane and regular skin) of the nail
- candidiasis (disease of mucous membrane and regular skin) of the nail.

EPIDEMIOLOGY

Frequency

United States:-The recent proliferation of fungal infections in the United States can be traced to the large immigration of dermatophytes, especially *Trichophyton rubrum*, from West Africa and Southeast Asia to North America and Europe.

International:-The incidence of onychomycosis has been reported to be 2-13% in North America. A multicenter survey in Canada showed the prevalence of onychomycosis at 6.5%. Onychomycosis accounts for half of all nail disorders, and onychomycosis is the most common

nail disease in adults. Toenails are much more likely to be infected than fingernails. Thirty percent of patients with a cutaneous fungal infection also have onychomycosis. The incidence of onychomycosis has been increasing, owing to such factors as diabetes, immunosuppression, and increasing age.

Studies in the United Kingdom, Spain, and Finland found prevalence rates of onychomycosis to be 3-8%.

Race

Onychomycosis affects persons of all races.

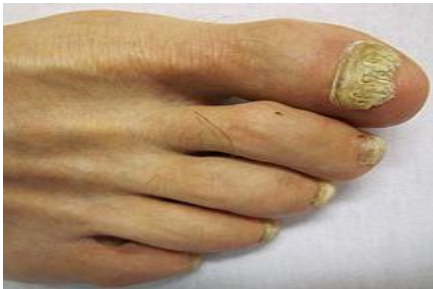Sex

Onychomycosis affects males more commonly than females. However, candidal infections are more common in women than in men.

Age

Studies indicate that adults are 30 times more likely to have onychomycosis than children. Onychomycosis has been reported to occur in 2.6% of children younger than 18 years but as many as 90% of elderly people.

SIGNS AND SYMPTOMS



The most common symptom of a fungal nail infection is the nail becoming thickened and discoloured: white, black, yellow or green. As the infection progresses the nail can become brittle, with pieces breaking off or coming away from the toe or finger completely. If left untreated, the skin can become inflamed and painful underneath and around the nail. There may also be white or yellow patches on the nail bed or scaly skin next to¹⁰ the nail.¹¹ There is usually no pain or other bodily symptoms, unless the disease is severe. People with onychomycosis may experience significant psychosocial problems due to the appearance of the nail, particularly when fingers – which are always visible – rather than toenails are affected.¹²

Dermatophytids are fungus-free skin lesions that sometimes form as a result of a fungus infection in another part of the body. This could take the form of a rash or itch in an area of the body that is not infected with the fungus. Dermatophytids can be thought of as an allergic reaction to the fungus.

PATHOPHYSIOLOGY

The pathogenesis of onychomycosis depends on the clinical subtype. In distal lateral subungual onychomycosis, the most common form of onychomycosis, the fungus spreads from plantar skin and invades the nail bed via the hyponychium. Inflammation occurring in these areas of the nail apparatus causes the typical physical signs of distal lateral subungual onychomycosis. In contrast, white superficial onychomycosis is a rarer presentation caused by direct invasion of the surface of the nail plate. In proximal subungual onychomycosis, the least common subtype, fungi penetrate the nail matrix via the proximal nail fold and colonize the deep portion of proximal nail plate. Endonyx onychomycosis is a variant of distal lateral subungual onychomycosis in which the fungi infect the nail via the skin and directly invade the nail plate. Total dystrophic onychomycosis involves the entire nail unit.

Nail invasion by *Candida* is not common because the yeast needs an altered immune response as a predisposing factor to be able to penetrate the nails. Despite the frequent isolation of *Candida* from the proximal nail fold or the subungual space of patients with chronic paronychia or onycholysis, in these patients *Candida* is only a secondary colonizer. In chronic mucocutaneous candidiasis, the yeast infects the nail plate and eventually the proximal and lateral nail folds.¹³

DIAGNOSIS OF ONYCHOMYCOSIS

Onychomycosis (OM) can be identified by its appearance. However, other conditions and infections can cause problems in the nails that look like onychomycosis. OM must be confirmed by laboratory tests before beginning treatment, because treatment is long, expensive, and does have some risks.¹⁴

- A sample of the nail can be examined under a microscope to detect fungi. See Anatomy of the Nail for information on the parts of the nail.
- The nails must be clipped and cleaned with an alcohol swab to remove bacteria and dirt so the fungal structures can be more easily visualized with a microscope.
- If the doctor suspects distal lateral subungual onychomycosis (DLSO), a sample (specimen) should be taken from the nail bed to be examined. The sample should be taken from a site closest to the cuticle, where the concentration of fungi is the greatest.
- If proximal subungual onychomycosis (PSO) is suspected, the sample is taken from the underlying nail bed close to the lunula.

- A piece of the nail surface is taken for examination if white superficial onychomycosis (WSO) is suspected.
- To detect candidal onychomycosis, the doctor should take a sample from the affected nail bed edges closest to the cuticle and sides of the nail.
- In the laboratory, the sample may be treated with a solution made from 20% potassium hydroxide (KOH) in dimethyl sulfoxide (DMSO) to help rule out or more easily verify the presence of fungi by reducing debris and human tissue in the sample. The specimen may also be treated with dyes (a process called staining) to make it easier to see the fungal structure through the microscope that help identify the precise species of the pathogen.
- If fungi are present in the infected nail, they can be seen through a microscope, but the exact type (species) cannot be determined by simply looking through a microscope. To identify what exactly is causing onychomycosis, a fungal culturing is used. Using a fungal culture to identify the particular fungus is important because regular therapy may not work on nondermatophyte molds.
 - ❖ The infected nail is scraped or clipped.
 - ❖ The scrapings or clippings are crushed and put into containers. Any fungus in the samples can grow in the laboratory in these special containers. This is true for most molds and yeast also.
 - ❖ The species of pathogen (usually a fungus) can be identified from the cultures grown in the lab by technicians trained to recognize the microscopic structures that are identifiers of the fungal species.

RISK FACTORS

Aging is the most common risk factor for onychomycosis due to diminished blood circulation, longer exposure to fungi, and nails which grow more slowly and thicken, increasing susceptibility to infection. Nail fungus tends to affect men more often than women, and is associated with a family history of this infection.¹⁴ Other risk factors include perspiring heavily, being in a humid or moist environment, psoriasis, wearing socks and shoes that hinder ventilation and do not absorb perspiration, going barefoot in damp public places such as swimming pools, gyms and shower rooms, having athlete's foot (tinea pedis), minor skin or nail injury, damaged nail, or other

infection, and having diabetes, circulation problems or a weakened immune system.

ONYCHOMYCOSIS PREVENTION

Although it may be impossible to prevent onychomycosis infections in everyone, there are ways to reduce a person's chance to get infected. The following are some of the methods to avoid nail infections:

- Remember that nail infections can be passed from person to person so washing hands (and feet) after contacting another person with nail infections is a good practice.
- Do not go barefoot in public showers or locker rooms.
- Use antifungal spray or powder in shoes, especially gym shoes.
- Be sure that if a manicure or pedicure is done, instruments are sterilized before each person is exposed to them.
- Keep feet dry and clean as possible.

Keep finger and toe nails trimmed; do not pick at or chew on fingernails or the skin around them.

TREATMENT OF ONYCHOMYCOSIS

Medications

In the past, medicines used to treat onychomycosis (OM) were not very effective. OM is difficult to treat because nails grow slowly and receive very little blood supply. However, recent advances in treatment options, including oral (taken by mouth) and topical (applied on the skin or nail surface) medications, have been made. Newer oral medicines have revolutionized treatment of onychomycosis. However, the rate of recurrence is high, even with newer medicines. Treatment is expensive, has certain risks, and recurrence is possible.¹⁵

- Topical antifungals are medicines applied to the skin and nail area that kill fungi and some other pathogens.
 - ❖ These topical agents should only be used if less than half the nail is involved or if the person with onychomycosis cannot take the oral medicines. Medicines include amorolfine (approved for use outside the United States), ciclopirox olamine (Penlac, which is applied like nail polish), sodium pyrithione, bifonazole/urea (available outside the United States), propylene glycol-urea-lactic acid, imidazoles, such as ketoconazole (Nizoral Cream), and allylamines, such as terbinafine (Lamisil Cream).

- ❖ Topical treatments are limited because they cannot penetrate the nail deeply enough, so they are generally unable to cure onychomycosis. Topical medicines may be useful as additional therapy in combination with oral medicines. This results in treatment medicine concentrations that come from two directions, topically and from within the body via oral medicine.
- Newer oral medicines are available. These antifungal medicines are more effective because they go through the body to penetrate the nail plate within days of starting therapy.
 - ❖ Newer oral antifungal drugs terbinafine (Lamisil Tablets) and itraconazole (Sporanox Capsules) have replaced older therapies, such as griseofulvin, in the treatment of onychomycosis. They offer shorter treatment periods (oral antifungal medications usually are administered over a three-month period), higher cure rates, and fewer side effects. These medications are fairly safe, with few contraindications (conditions that make taking the medicine inadvisable), but they should not be taken by patients with liver disease or heart failure. Before prescribing one of these medications, doctors often order a blood test to make sure the liver is functioning properly. Common side effects include nausea and stomach pain.
 - ❖ Fluconazole (Diflucan) is not approved by the Food and Drug Administration (FDA) for treatment of onychomycosis, but it may be used by some clinicians as an alternative to itraconazole and terbinafine.
- To decrease the side effects and duration of oral therapy, topical and surgical treatments (see below) may be combined with oral antifungal management.¹⁷

Surgery

Surgical approaches to onychomycosis treatment include surgically or chemically removing the nail.¹⁸

- Thick nails may be chemically removed by using a urea compound. This technique

usually should be deferred to a surgeon or dermatologist.

- Surgically removing the nail plate is not effective treatment of onychomycosis without additional therapy. This procedure should be considered an adjunctive (additional) treatment combined with oral medical therapy.
- A combination of oral, topical, and surgical therapy may increase the effectiveness of treatment and reduce the cost of ongoing treatments.

Laser Treatment

One of the newest treatments to kill pathogens infecting the nails is laser therapy. The laser beam can penetrate the nail tissue and disrupt fungal and other pathogens enough to kill them. Some patients may experience some mild discomfort during the procedure. Reports suggest that laser therapy is about as effective as medical therapy¹⁹. Some patients may require more than one treatment. This treatment can be very expensive.

Alternative Treatments

There are many claims made that home remedies can be used to treat a fungal nail infection. Products such as Listerine, VapoRub, beer soaks, peroxide, and others are purported to be effective. Unfortunately, there is little or no data to support these claims; some of the commercially available products do not promote their use for nail infections although some individuals may use them for alternative treatments¹⁹.

CONCLUSION

Although regional and temporal variability exists among the microorganisms that are pathogenic in onychomycosis, this disease is caused primarily by dermatophytes. After decades of frustration and disappointment with this stubborn infection, dermatologists and other clinicians now have access to drugs with high cure rates and excellent safety profiles. Moreover, short treatment times increase patient compliance, reduce treatment costs, and allow patients to feel hopeful that their unsightly infections will be ended.

Perhaps the most important task of the clinician is accurate diagnosis of the causal agent. Direct microscopy and culture are both necessary to ensure this. Selection of an optimal antifungal drug whose spectrum of activity encompasses the infecting microorganism can proceed only with accurate diagnosis.

In the last decade, there have been significant advances in the development of effective and safe drugs for onychomycosis. What remains to be achieved? Unfortunately, onychomycosis is likely to remain a disease of modern civilization²⁰. The environmental conditions that foster it, longer life

expectancies, and the increasing numbers of immunocompromised individuals have combined to increase its prevalence. Against this trend are the new antifungal drugs itraconazole, terbinafine, and fluconazole. But perhaps the single area most deserving of our attention in the near future is that of improving diagnostic methods. Diagnostic methodology and fungal susceptibility testing lag behind therapeutic advances. We should turn our attention to these problems.

REFERENCES

- Rapini, Ronald P.; Bologna, Jean L.; Jorizzo, Joseph L. (2007). *Dermatology: 2-Volume Set*. St. Louis: Mosby. p. 1135. ISBN 1-4160-2999-0. 16262878.
- "onychomycosis" at Dorland's Medical Dictionary.
- Szepietowski JC, Salomon J (2007). "Do fungi play a role in psoriatic nails?". *Mycoses* 50 (6): 437–42. doi:10.1111/j.1439-0507.2007.01405.x. PMID 17944702.
- "Impact 07 - Dermatology" (PDF). *Bay Bio*. 2007. Retrieved 2007-06-13.
- James, William D.; Berger, Timothy G. (2006). *Andrews' Diseases of the Skin: clinical Dermatology*. Saunders Elsevier. ISBN 0-7216-2921-0.
- Cmecorner.com. Retrieved 2010-08-05.
- Szepietowski JC, Reich A (September 2008). "Stigmatisation in onychomycosis patients: a population-based study". *Mycoses* 52 (4): 343. doi:10.1111/j.1439-0507.2008.01618.x. PMID 18793262.
- Chi CC, Wang SH, Chou MC (2005). "The causative pathogens of onychomycosis in southern Taiwan". *Mycoses* 48 (6): 413–20. doi:10.1111/j.1439-0507.2005.01152.x. PMID.
- Clayton, Y. M., and R. J. Hay. 1993. Epidemiology of fungal skin and nail disease: roundtable discussion held at Dermatology 2000, Vienna, 17 May 1993. *Br. J. Dermatol.* 130(Suppl. 4):9–11.
- Clinical Courier. New strategies for the effective management of superficial fungal infections. *Clin Courier*. 1997;16:2–3.
- http://www.emedicinehealth.com/onychomycosis/discussion_em-739.htm.
- Goodfield, M. J. D. 1992. Short-duration therapy with terbinafine for dermatophyte onychomycosis: a multicentre trial. *Br. J. Dermatol.* 126(Suppl. 39):33–35.
- Ellis, D. H., J. E. Marley, A. B. Watson, and T. G. Williams. 1997. Significance of non-dermatophyte molds and yeasts in onychomycosis. *Dermatology* 194(Suppl. 1):40–42.
- De Doncker P. Pharmacokinetics of oral antifungal agents. *Dermatol Ther.* 1997;3:46–57.
- Winn W C., Jr . Mycotic diseases. In: Henry J B, editor. *Clinical diagnosis and management*. Philadelphia, Pa: The W. B. Saunders Co.; 1996. pp. 1210–1251.
- Summerbell R C, Kane J, Krajden S. Onychomycosis, tinea pedis, and tinea manuum caused by non-dermatophytic filamentous fungi. *Mycoses*. 1989;32:609–619.
- Zaias N, Tosti A, Rebell G, Morelli R, Bardazzi F, Bieleley H, Zaiac N, Glick B, Paley B, Allevalo M, Baran R. Autosomal dominant pattern of distal subungual onychomycosis caused by *Trichophyton rubrum*. *J Am Acad Dermatol.* 1996;34(2 Pt 1):302–304.
- http://emedicine_medscape_com/article/1105828-treatment#a1127.
- Del Rosso J Q. Advances in the treatment of superficial fungal infections: focus on onychomycosis and dry tinea pedis. *J Am Osteopath Assoc.* 1997;97:339–345.
- Gupta AK, Shear NJ. The new oral antifungal agents for onychomycosis of the toenails. *J Eur Acad Dermatol Venereol* 1999; 13:1–3.